Large-vessel vasculitis with persistent exertional dyspnea in a 75-year-old woman

Shiro Miura, MD, MSc,[a] Masanao Naya, MD, PhD,[b] Osamu Manabe, MD, PhD,[c] and Takehiro Yamashita, MD, PhD, FACC[a]

[a] Department of Cardiology, Hokkaido Ohno Memorial Hospital, Sapporo, Japan
[b] Department of Cardiovascular Medicine, Hokkaido University Graduate School of Medicine, Sapporo, Japan
[c] Department of Radiology, Jichi Medical University Saitama Medical Center, Saitama, Japan

Received Jul 13, 2021; accepted Jul 14, 2021
doi:10.1007/s12350-021-02753-0

Abbreviations

CMD	Coronary microvascular dysfunction
CT	Computed tomography
FDG	Fluorodeoxyglucose
MFR	Myocardial flow reserve
PET	Positron emission tomography
RPR	Rate–pressure product

CASE SUMMARY

A 75-year-old woman presented with low-grade fever, and pain and numbness in her upper extremities that worsened on exertion, for over three months, (Raynaud's phenomenon) (Figure 1). She also had persistent exertional dyspnea. Her electrocardiographic and transesophageal echocardiographic findings were within the normal ranges. Computed tomography (CT) angiography revealed multiple stenoses in both mid-subclavian arteries and occlusion from the axillary to the brachial arteries bilaterally (Figure 2). Subsequent invasive coronary angiography demonstrated intermediate

Reprint requests: Shiro Miura, MD, MSc, Department of Cardiology, Hokkaido Ohno Memorial Hospital, 2-1-16-1 Miyanosawa, Nishi-ku, Sapporo063-0052, Japan; *s.miura@ohno-kinen.or.jp*
J Nucl Cardiol
1071-3581/$34.00

Published online: 26 July 2021

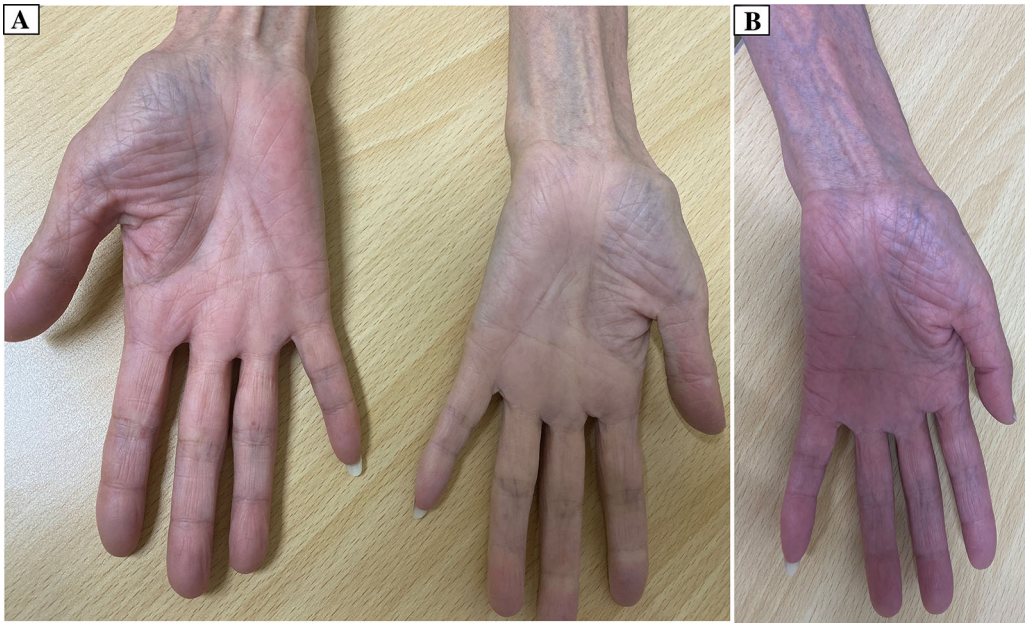

Figure 1. The left hand turned pale after repetitive hand grip (**A**), then returned to normal when warmed (**B**), in contrast to the normal right hand.

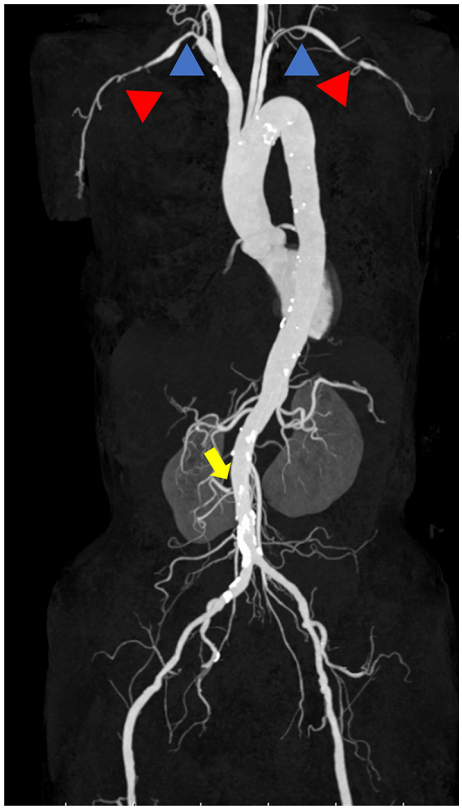

Figure 2. Three-dimensional reconstruction of the great arteries by computed tomography demonstrates stenoses in both the mid-subclavian arteries (blue arrowheads) and total long occlusion from the axillary to brachial arteries (red arrowheads) in both arms, without any significant stenosis of the thoracoabdominal aorta. Focal ostial stenosis of the right renal artery (yellow arrow) is evident.

stenotic lesions at the ostium of the right and left coronary arteries (Figure 3). ^{18}F-fluorodeoxyglucose (FDG) positron emission tomography (PET)/CT revealed an increased FDG uptake in the thoracoabdominal aorta and along the carotid and subclavian arteries (Figure 4A). Laboratory examination showed a white blood cell count of 8200/mm^3 and erythrocyte sedimentation rate of 81 mm·h. Blood cultures and serologic tests were negative for hepatitis B, hepatitis C, human immunodeficiency virus, and syphilis. The above findings were suggestive of Takayasu's arteritis. Her stress/rest perfusion ^{13}N-ammonia PET/CT demonstrated (Figure 5A) a significantly low global

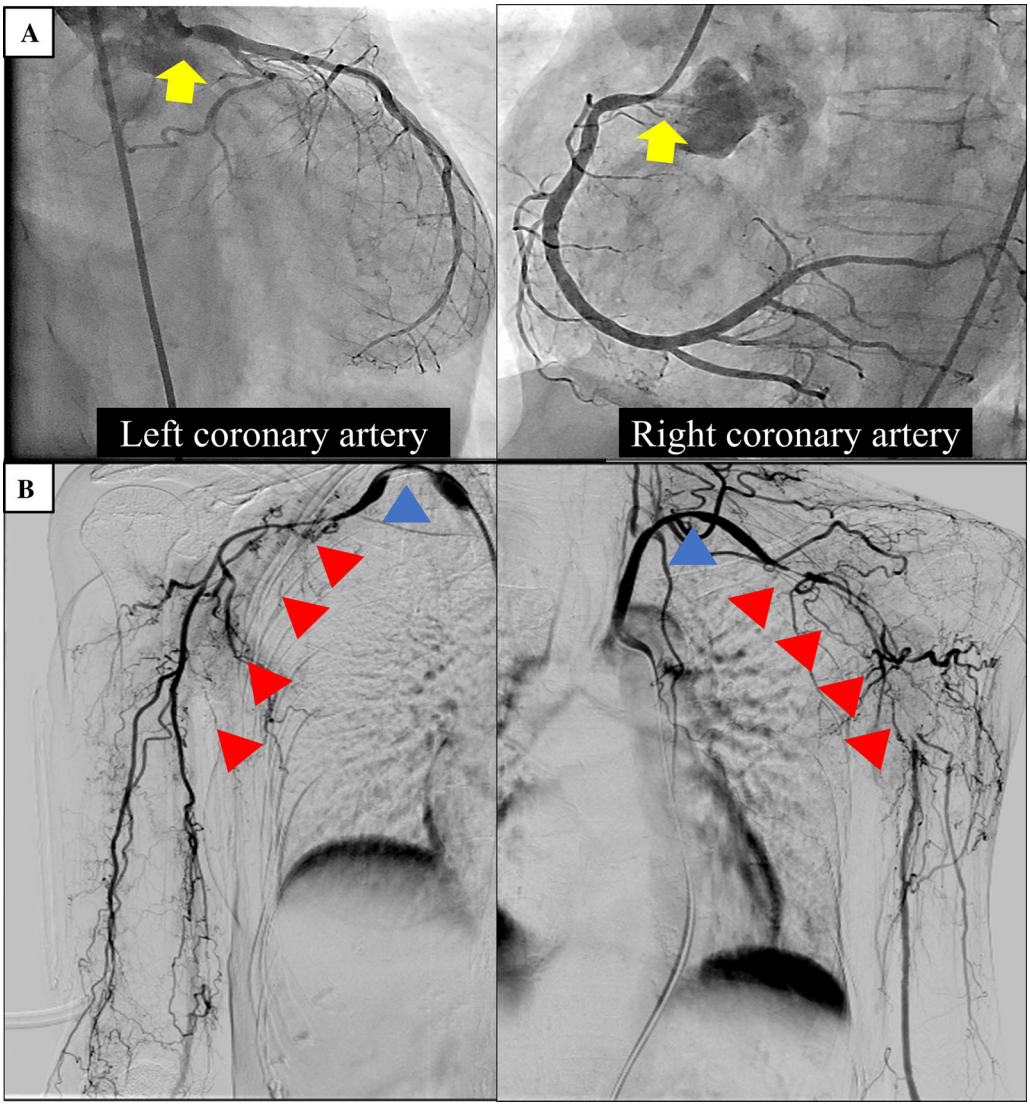

Figure 3. Invasive coronary angiography (**A**) demonstrates unobstructed epicardial coronary arteries with intermediate ostial stenoses (yellow arrows) in the left (**A**, left) and right coronary arteries (**A**, right), assessed at 42% and 31%, respectively, through qualitative comparative analysis. Digital subtraction angiography (**B**) confirms significant stenosis (blue arrowheads) of the bilateral subclavian arteries and occlusion from the axillary to brachial arteries bilaterally (red arrowheads).

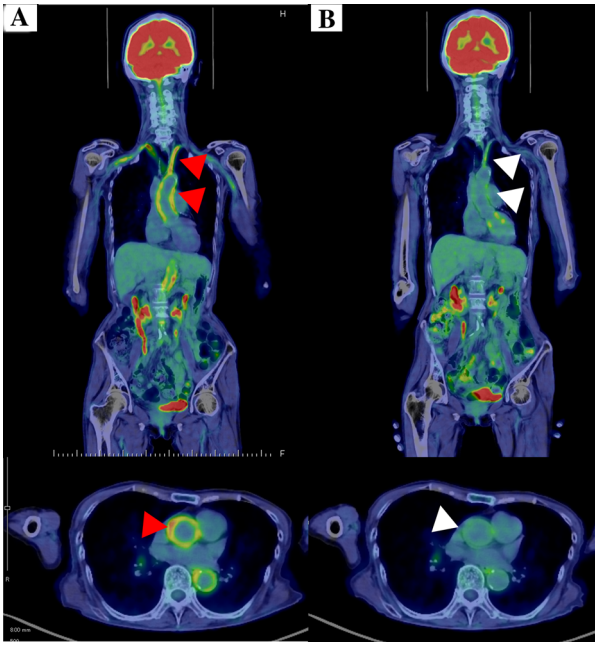

Figure 4. Initial ^{18}F-fluorodeoxyglucose (FDG) positron emission tomography (PET)/CT demonstrates increased FDG uptake in the thoracoabdominal aorta, and along the carotid and subclavian arteries (red arrows), with a single horizontal slice at the pulmonary trunk level (**A**). In contrast, the enhanced FDG uptake (white arrowheads) almost disappeared after the 3-week oral corticosteroid therapy (**B**).

myocardial flow reserve (MFR) of 1.82. However, myocardial perfusion imaging appeared normal, suggesting coronary microvascular dysfunction (CMD). She was treated with oral prednisone. Inflammatory parameters normalized within three weeks, and the numbness and pain in her arms disappeared. On repeated FDG-PET/CT, no remarkable uptake along the aortic wall and subclavian arteries was noted (Figure 4B). Three months after the initiation of corticosteroid therapy, she still complained of dyspnea on exertion. A repeat ^{13}N-ammonia PET/CT (Figure 5B) revealed a low global MFR of 2.09. These findings imply that conventional corticosteroid treatment may not improve angina and CMD over the short-term. CMD has been described in similar chronic inflammatory conditions, such as systemic lupus erythematosus, where prolonged vascular inflammation contributes to endothelial dysfunction and reduced MFR.[1] However, this is the first report that

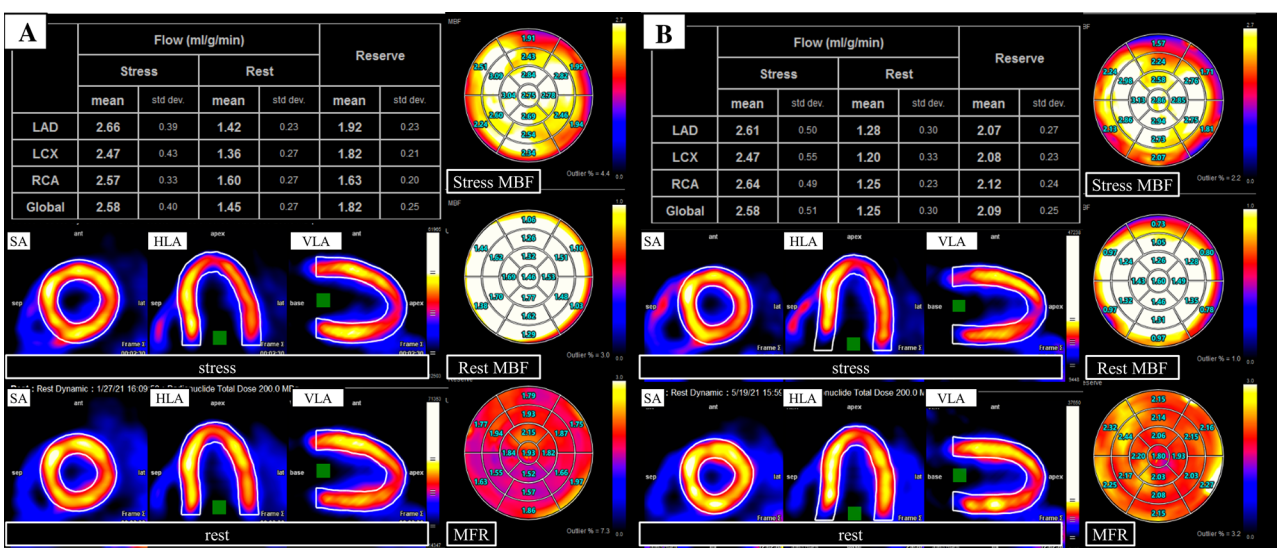

Figure 5. Comparison of the initial (**A**) and repeat (**B**, after 3 months of corticosteroid therapy) ATP-induced stress and rest ^{13}N-ammonia PET/CT. The initial global myocardial blood flow (MBF) at stress and rest were 2.58 and 1.45 mL·min^{-1}g^{-1}, respectively; the initial and follow-up myocardial flow reserve (MFR) were 1.82 (rate–pressure product [RPP]-corrected MFR, 1.56) (A, left) and 2.09 (RPP-corrected MFR, 1.45), respectively, with the stress MBF unchanged at 2.58 mL·min^{-1}g^{-1} (**B**, left). These findings were similar in the 17-segment between the initial and follow-up PET examinations (**A**, right and **B**, right). Myocardial perfusion imaging in the short axis (SA), vertical long axis (VLA), and horizontal long axis (HLA) showed no significant reduction in tracer uptake during stress and rest phases in both studies (**A**, bottom and **B**, bottom).

associates large-vessel vasculitis with CMD, as evidenced by perfusion PET.

Disclosures

The authors indicate that they have no financial conflict of interest.

Reference

1. Behar JM, Bratis K, Clapp B, Nagel E. Refractory ischaemic chest pain caused by microvascular coronary dysfunction in a large vessel vasculitis. Eur Heart J Cardiovasc Imaging 2016;17:702